

# *Endovascular management of aortic trauma in a young patient*

Claudio M. Cigalini, MD; Roberto Larghi, MD; Martín Najenson, MD; Lucas Medizza, MD; Federico García Grecco, MD; María C. Masino, MD; Santiago Milano, MD; Ignacio Carossi, MD; Ignacio M. Ciglaini, MD

# Disclosure Statement of Financial Interest

I, **Claudio Cigalini**, DO NOT have a financial interest/arrangement or affiliation with one or more organizations that could be perceived as a real or apparent conflict of interest in the context of the subject of this presentation.

Faculty disclosure information can be found on the app

# 19 year-old male

Risk factors: none

Prior medical history: epilepsy (levetiracetam 1gr bid)

**Presentation:** *severe polytrauma* resulting from a horse fall during COVID-19 outbreak.

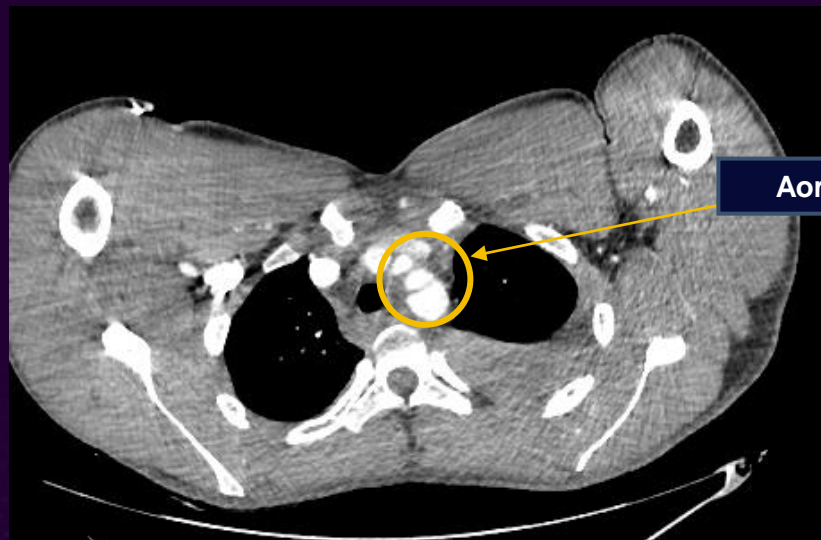## Physical exam:

- BP 140/90 mmHg in both arms, 114 bpm.
- Glasgow Comma Score 15/15
- Bilateral bipalpebral haematoma, multiple contusions and bruising on the facial mass and thorax.
- **Multifocal 2/6 systolic murmur**
- Left lung hypoventilation (midfield to base) with pain on palpation.

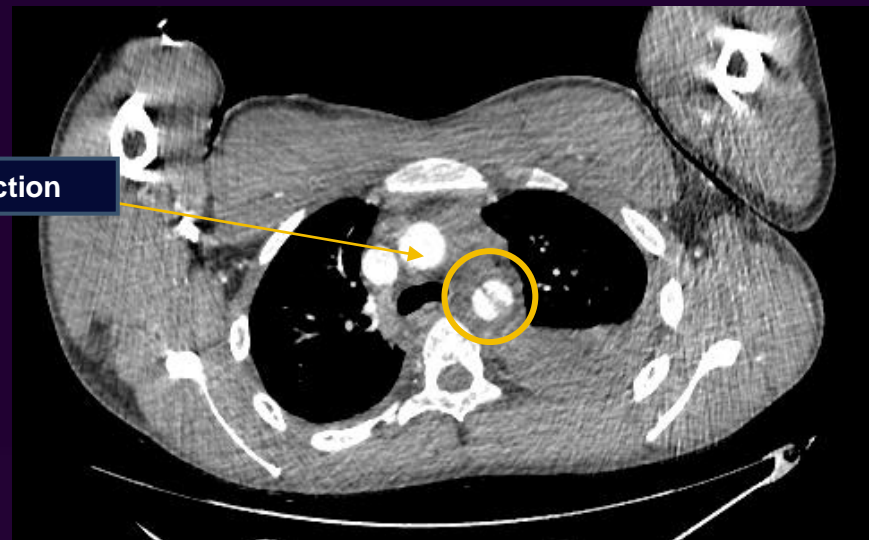
## Laboratory investigations:

<b>Hct</b>	39%	<b>Creatinine</b>	0.94 mg/dl
<b>Hb</b>	13,5 g/dl	<b>Lactid Acid</b>	19,5 mg/dl
<b>WBC</b>	25.800 /mm <sup>3</sup>	<b>pH</b>	7.39
<b>Platlet Count</b>	213.000 / mm <sup>3</sup>	<b>HCO<sub>3</sub></b>	17,7 mEq/L
<b>Glucose</b>	215 mg/dl		

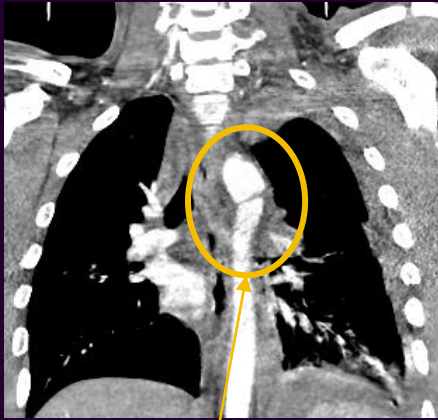
# CTMS



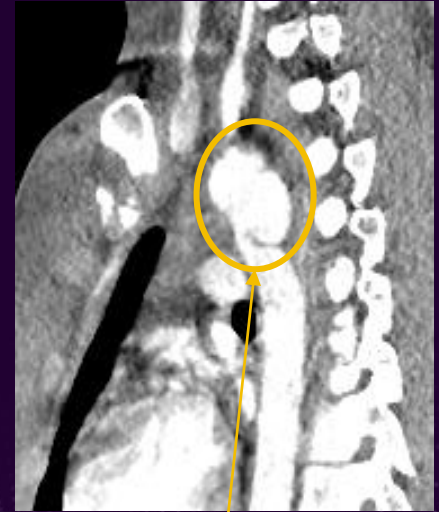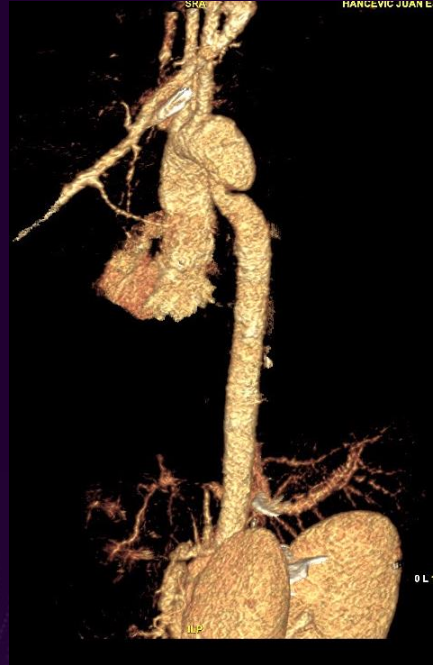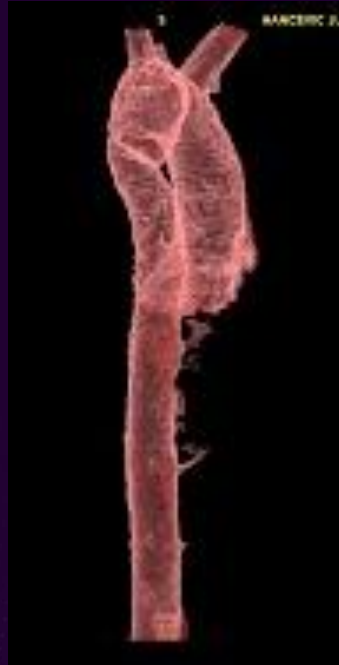Aortic dissection



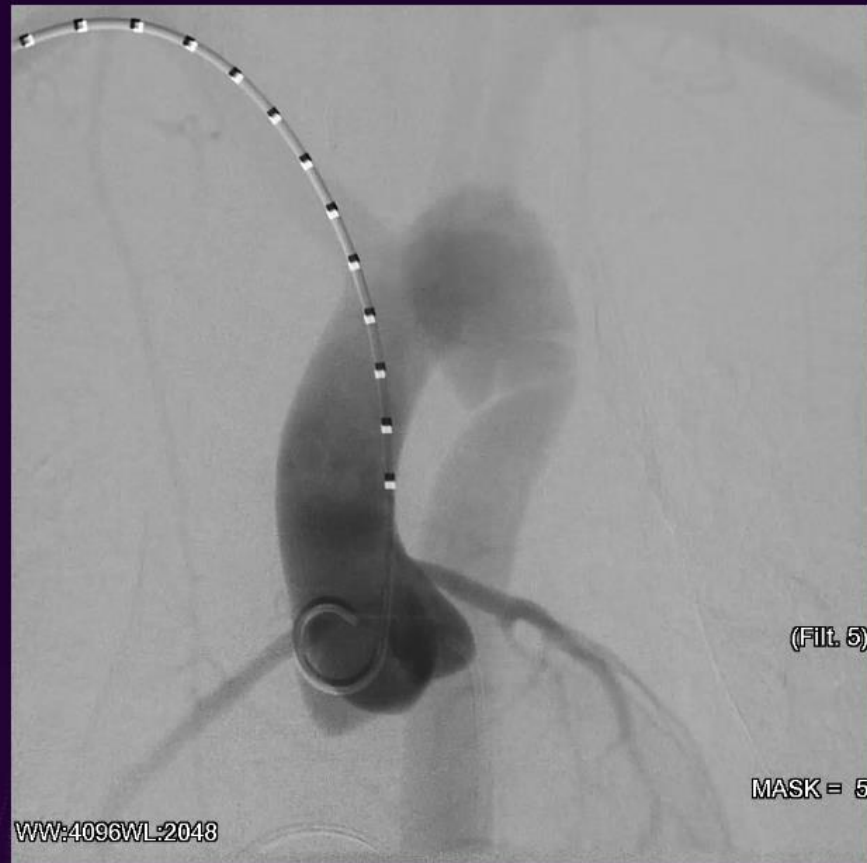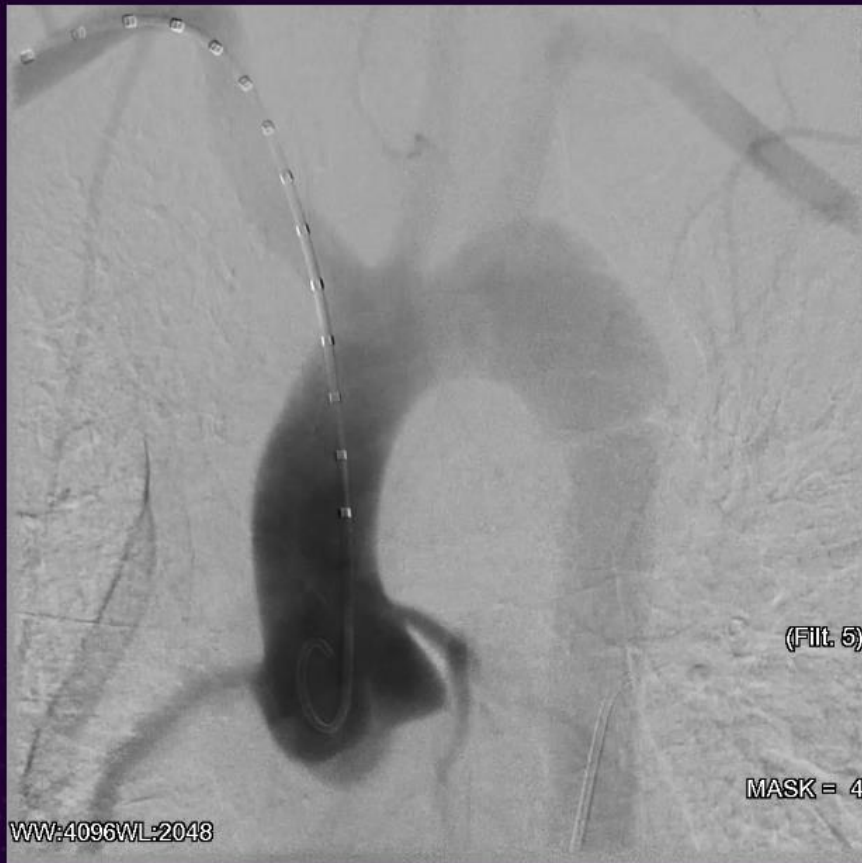# CTMS



Pseudocoarctation

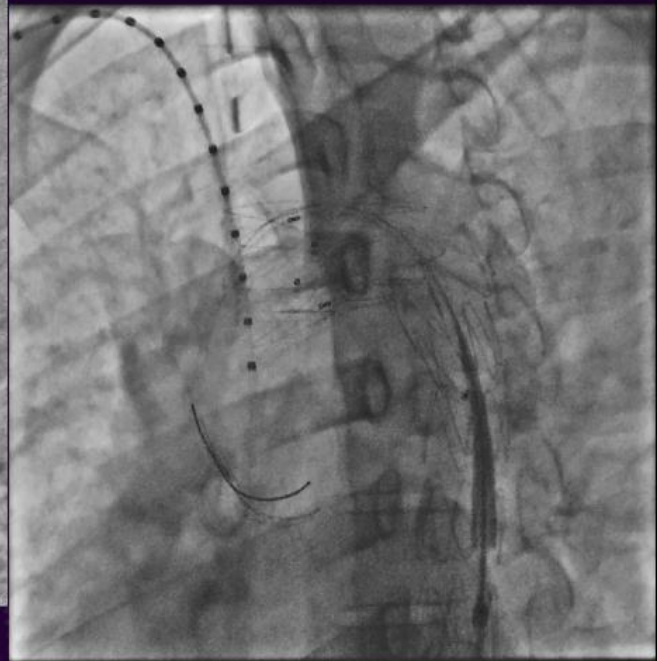
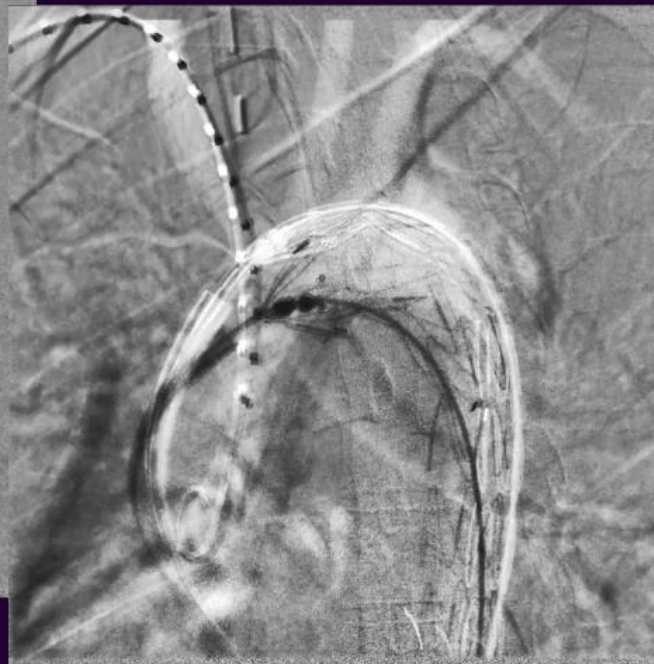
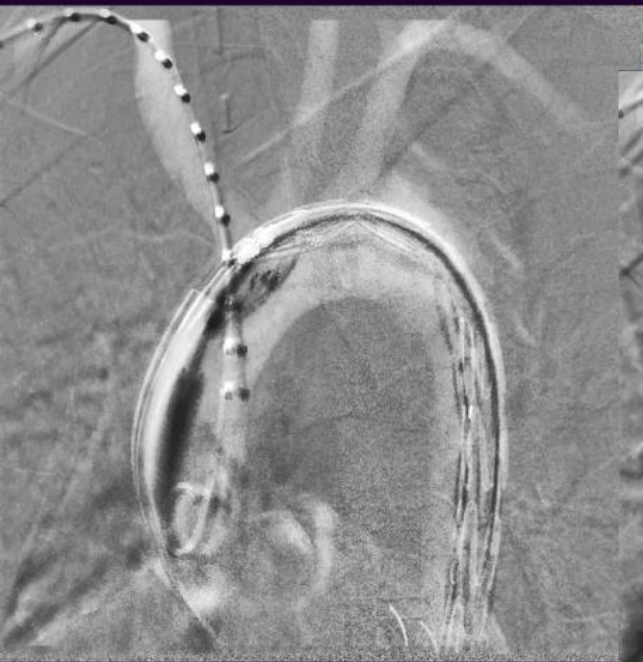Pseudoaneurysm



# Angiography

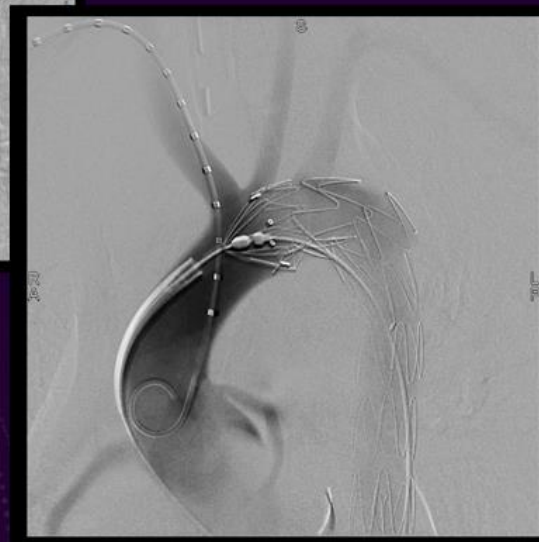
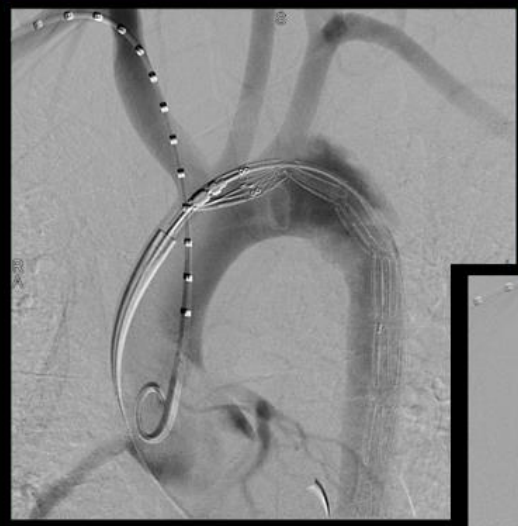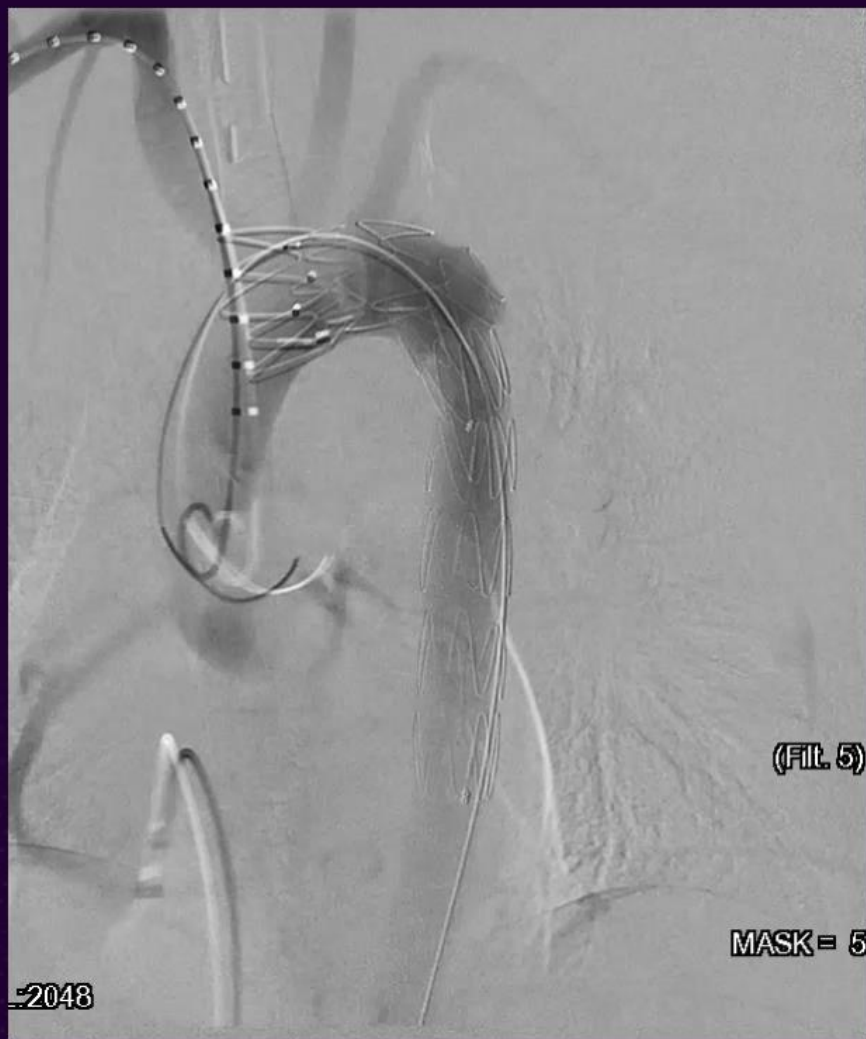# TEVAR



Microport Hercules 24/22-160mm

CRF  
TCT CONNECT

TEVAR



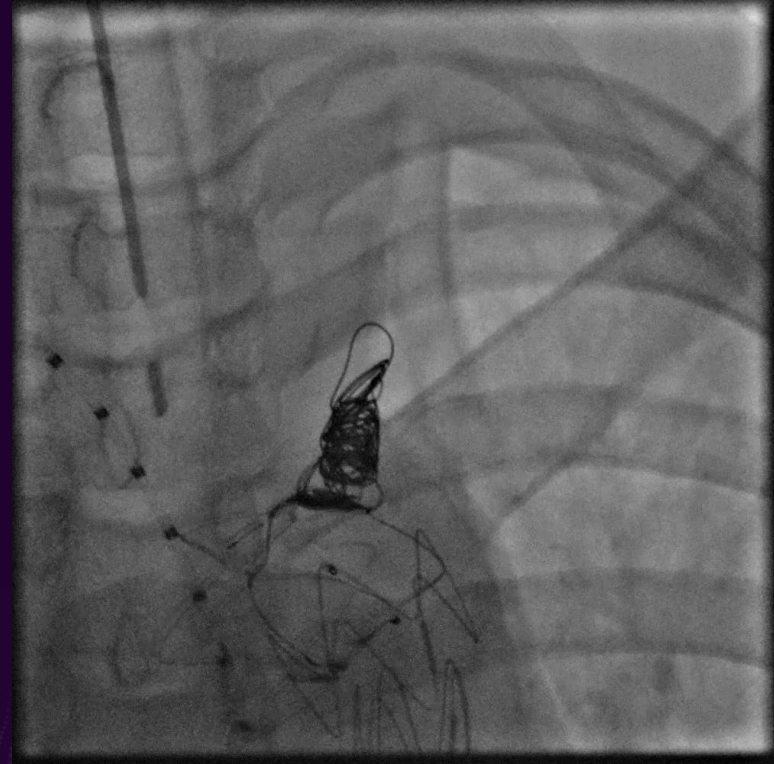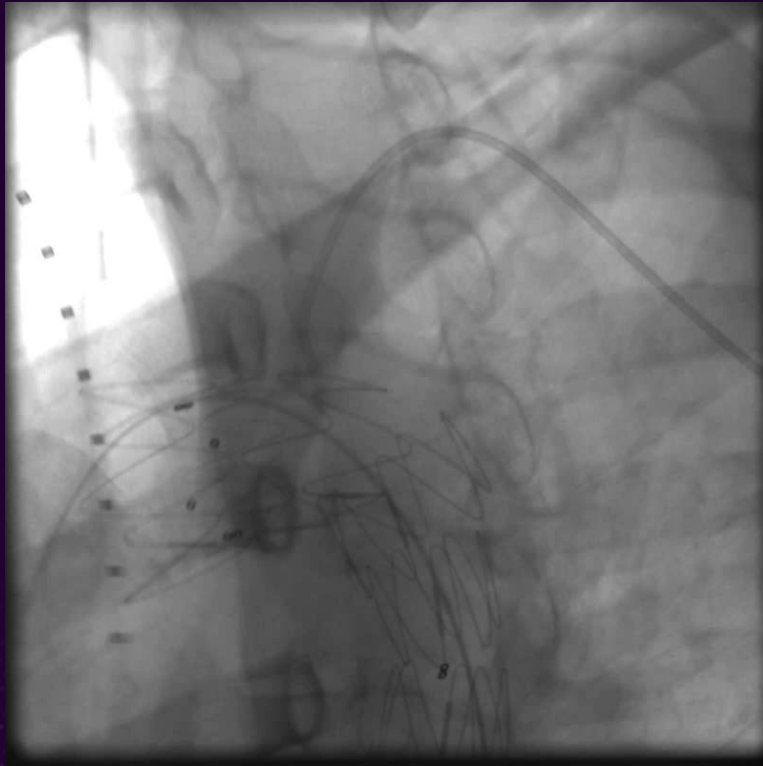-2048

(FIL. 5)

MASK = 5

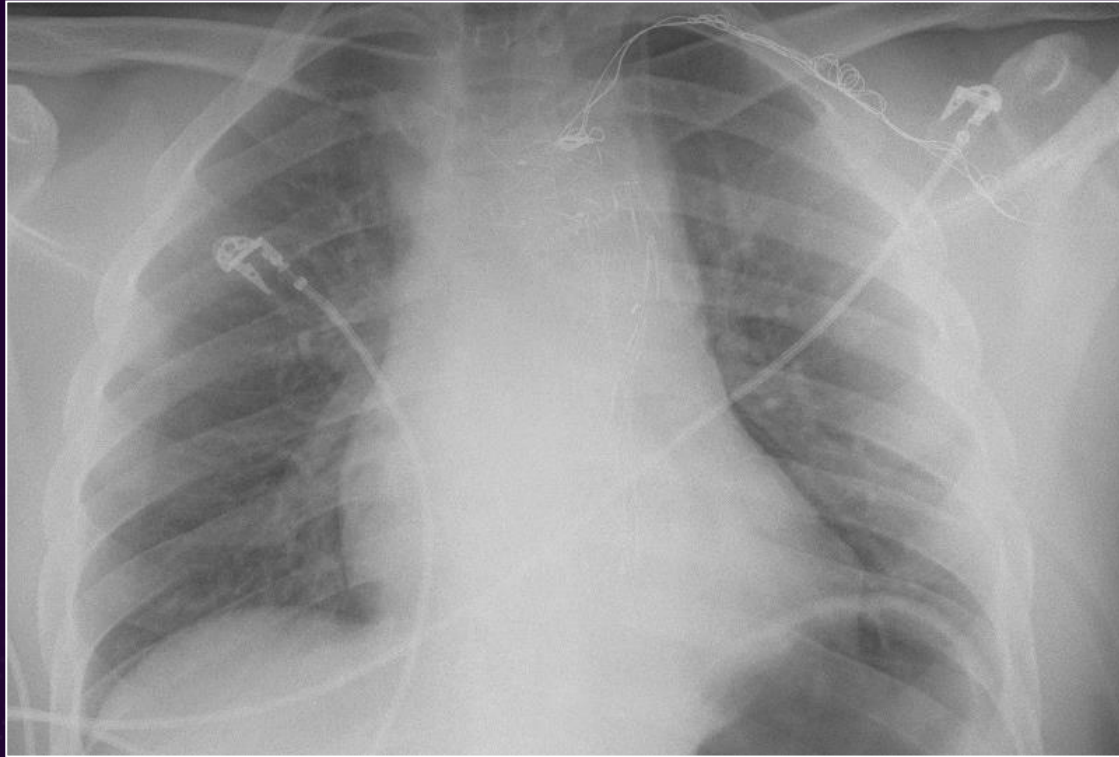


## Oclusion of left subclavian artery

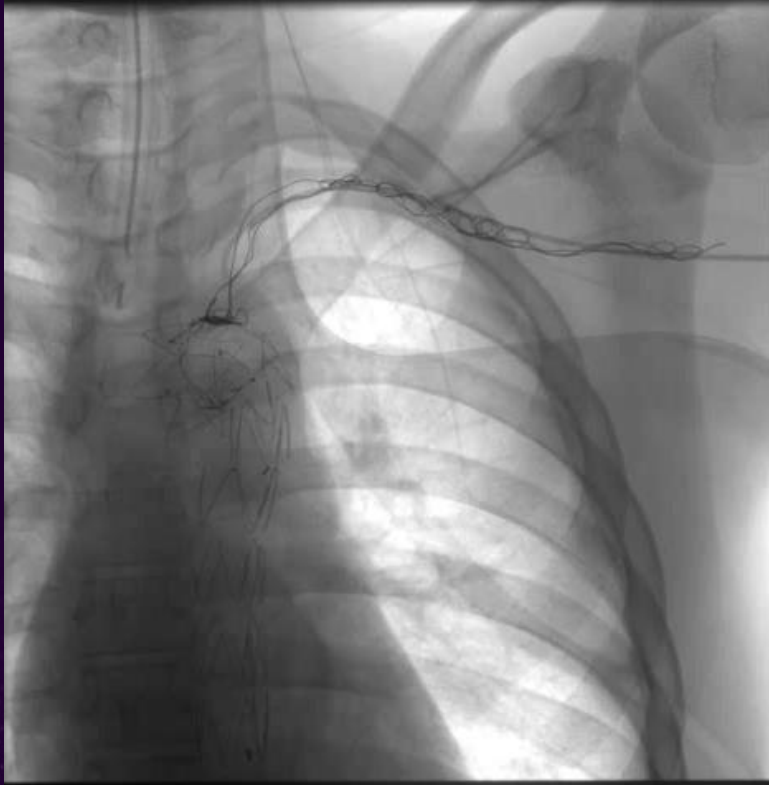

Medtronic Concerto 12x40 3D,  
16x40 3D and 9x30 helix

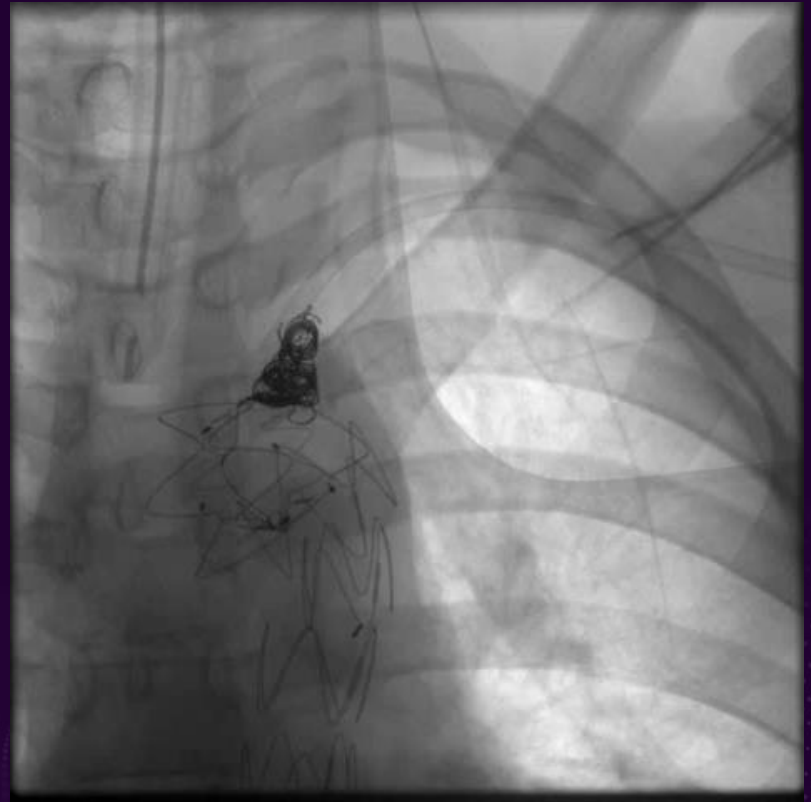
# Chest X-Ray (24h)



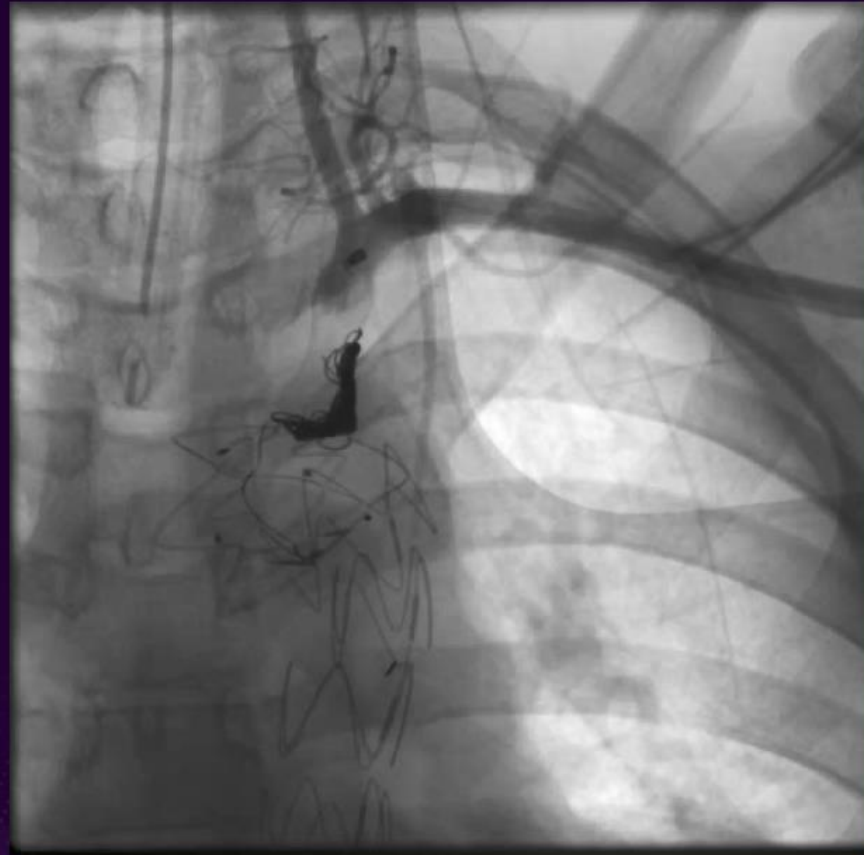Partial migration of coils without arm compromise



Coils repositioning using a snare



# Implant of vascular plug on left subclavian artery



**Memopart  
Occluser plug  
18mm**

# Follow-up CTMS

